

Clinical Photodynamics

In Dermatology

An International Newsletter for PDT and FD in Clinical Practice

Editorial

Topical PDT has reached its 21st 'Birthday': topical PDT with endogenous protoporphyrin IX has come of age! Since Kennedy's publication* on topical PDT saw the dawn of the modern era of interest in PDT for skin disease, we have seen many studies confirm its efficacy in actinic keratoses, Bowen's disease and basal cell carcinoma, leading to licences for its use in many parts of the world. A wealth of research also attests to its potential in many other disease indications. Research continues to refine and extend the use of PDT in clinical practice. In this issue of *Clinical Photodynamics*, a selection of recent publications on novel indications and ways of improving delivery of PDT is summarised.

PDT features prominently at international dermatology meetings, with a review of the recent EADV Congress in Gothenburg in this issue. A report on the 8th International Symposium on PDT and Photodiagnosis in Clinical Practice in Brixen, also published in this issue, reminds us that PDT has potential across several specialties. There were well-attended symposia on PDT at this year's American Academy of Dermatology Meeting in New Orleans (February 4-8). Presentations included a comprehensive review of PDT's potential in acne, another

important future indication, if a protocol can be optimised that delivers prolonged improvement after a small number of treatments with acceptable adverse reaction profile.

Given the research interest, it is frustrating that, 21 years on, PDT has yet to become a widely available routine therapy, moving to become a useful therapy platform for many disease indications.

This year's Euro-PDT meeting in Paris, March 11-12 will showcase the latest thinking on PDT in skin disease, with a full report in the next issue of *Clinical Photodynamics*.

We welcome feedback and articles/meeting reports! Subject to the availability of space, the Editorial Board of *Clinical Photodynamics* welcomes articles on PDT and fluorescence diagnosis in dermatological practice. Please contact us with your ideas at eurocommunica@sky.com.

Colin Morton, Stirling, UK

*Kennedy JC, Pottier RH, Pross DC, 1990 Photodynamic therapy with endogenous protoporphyrin IX: basic principles and present clinical experience. *J Photochem Photobiol B: Biol* 6 143-148

19th Congress of the European Academy of Dermatology and Venereology (EADV)

6-10 October, 2010
Gothenburg, Sweden

by: Dr Colin Morton
Stirling, UK

Gothenburg (Göteborg) is the second largest city in Sweden and this was the first time the EADV has been held in Sweden. The Congress was well organised under the Presidency of Prof Olle Larko. There were

a number of presentations on PDT, including a specific workshop which highlighted new applications, as well as 13 posters which reported on the use of PDT in skin disease.

The PDT workshop was chaired by Prof Anne-Marie Wennberg, of the host city's University Hospital, and Prof Rolf-Markus Szeimies from Recklinghausen, Germany. The workshop was well attended, despite its Saturday morning 8am timeslot, and the audience were rewarded with the crisp sum-



Gothenburg city street.

mary of new photosensitising formulations for PDT by Prof Szeimies. He updated the audience on publications, describing the use of a patch specially impregnated with

Editorial Board

Prof Peter Foley Melbourne, Australia
Dr Sigrid Karrer Regensburg, Germany
Dr Colin Morton Stirling, Scotland
Prof Ann-Marie Wennberg Göteborg, Sweden

In this Issue

| | |
|---|---|
| 19th Annual Congress of the EADV | 1 |
| 8th International Symposium on Photodynamic Therapy and Photodiagnosis in Clinical Practice | 4 |
| Prime Time PDT | 7 |
| Calendar of Events 2011 | 8 |

5-ALA that has been demonstrated to be highly effective in the treatment of actinic keratosis (AK), superior to cryotherapy, and with sustained clearance rates out to 12 months in a recent follow-up study. Another patch, containing 5-ALA, is also under evaluation for its potential in the treatment of vaginal intraepithelial neoplasia, helping to respond to the challenge of photosensitiser application at this site. The patches hold the promise of helping to simplify PDT and to extend the choice of formulation of photosensitiser available in the clinic. A novel nanoemulsion of 5-ALA has also been evaluated in AK, using two different non-laser light sources, with remarkably high efficacy rates achieved when the red LED light source was used, with lesion clearance rates at 3 months after treatment of 99%. A study comparing 1-hour versus 3-hour application of methyl aminolevulinate (MAL: Metvix[®]) has shown no significant inferiority with the shorter application time in the treatment of mild-to-moderate AK, opening the possibility of added efficiency in delivery of PDT, although the licence is to use MAL for 3 hours.

Dr Merete Haedersdal (Copenhagen, Denmark) discussed increasing the delivery of sensitisers using a fractional CO₂ laser. Ablative fractional resurfacing creates vertical channels that may enable an improved PDT response to deeper skin lesions. In an in vivo experiment using pigs, a fractional CO₂ laser was used to create the channels, followed by the application of MAL under occlusion for 3 hours, then illumination using a red LED light. PDT responses were assessed at between 120-1800µm in depth and fluorescence intensity was assessed. In the presence of laser-ablated channels, there was enhanced biodistribution of MAL in both superficial and deep skin layers, permitting higher skin fluorescence than when MAL was applied to unprepared skin. It is hypothesised that this technique could be used to improve clinical responsiveness of thicker skin lesions to PDT.

I undertook to review the status of topical PDT in epithelial skin cancer. I underlined that 3-month efficacy rates by lesion response with MAL-PDT using red LED in AK would expect to achieve clearance rates of 89-92% after a single treatment, repeated at 3 months if required, with the use of the ALA patch achieving similar efficacy in a single treatment of 82-89%. MAL-PDT has been reported to achieve clearance rates at 6 months of 89% with the patch PDT described in this report achieving 12 months clearance rates of between 63-79%, whilst a large study using Levulan[®] ALA-PDT achieved clearance at 12 months of 78%.

For Bowen's disease, MAL-PDT achieves 3-month clearance rates of 93%, and recurrence

rates, equivalent to standard therapy, of 18% by 24 months. Given the high proportion of PDT lesions developing on the lower legs, or similar sites of poor healing, and hence poor tolerance of cryotherapy, PDT remains a strong option for both AK and Bowen's disease, where the cosmetic benefits and wound-healing advantages are important, given the sites typically treated.



The Poseidon Fountain.

Evidence remains, however, that whilst PDT should be considered a first choice option for in-situ squamous cell carcinoma (SCC: Bowen's disease), efficacy begins to fall away with microinvasive lesions, with 24-month clearance rates in one study of 71% for in-situ SCC, but just 58% at 24 months for microinvasive lesions. Efficacies are considerably poorer for invasive SCC, and it remains advisable not to use PDT for invasive lesions

and to consider its use in microinvasive disease only where the opportunity for regular follow-up can be provided.

There has been little recent change in the literature concerning PDT in basal cell carcinoma (BCC). Initial clearance rates with MAL-PDT for superficial BCC are 92-97% at 3 months, equivalent to cryotherapy but inferior to surgery. Over a 5-year period, approximately 20% of lesions may recur following PDT, the equivalent recurrence rate to cryotherapy. For nodular BCC, initial 3-month clearance rates of 91% were achieved for PDT compared to 98% for surgery, but 14% of lesions recurred during 5 years of follow-up, compared to 4% with surgery. Patient and lesion selection therefore remain important when considering PDT for nodular BCC.

Prof Wennberg discussed the issues influencing the experience of pain in PDT, with large lesions, diagnosis of AK, lesion site on the head and scalp, as well as the redness of lesions and male gender, all shown to be indicative of greater experience of pain. A number of methods of pain reduction have been described, but the benefits achieved through talk anaesthesia and the use of a fan and spraying cold water on treatment sites should not be underestimated, and the use of a nerve block for large scalp areas has been demonstrated to offer considerable benefits in patients receiving PDT for field change lesions.

Dr Robert Bissonnette (Montreal, Canada) described an open-label, single-centre study with 20 subjects, where at least 5 facial non-hyperkeratotic AK were treated with MAL-PDT followed by illumination with a



Swedish Exhibition Centre (EADV Congress venue).



Gothenburg Harbour.

red LED light source, 90 minutes after cream applications. A second treatment was repeated at week 4, if required. Preliminary data showed a reduction in lesions of 75%.

In a study that has echoed my own experience of PDT in Bowen's disease, **Dr Alvarez Fernandez** (Alcorcon, Spain) described his group's experience of treating 86 patients with 98 Bowen's disease lesions, with a clinical response rate of 84% and the recommendation that PDT be considered the gold standard for Bowen's disease.

Dr Laurent Parmentier (Berne, Switzerland) reported a retrospective study of 15 BCC arising on sites of previous PDT. All recurrences were excised. Nine of the 15 BCC showed a progression from a low to a high aggressive histological form. The authors of this study conclude that PDT should be used with caution in non-superficial BCC, with regular follow-up advised.

Dr Stefano Piaserico (Padova, Italy) discussed the potential of topical PDT in granulomatous skin disorders. PDT can clear around 10% of granuloma annulare lesions, with 40% of lesions showing a good response. In necrobiosis lipoidica, a 50% good response rate (although 0% complete response) has been observed. A few case reports also suggest the potential of PDT in cutaneous sarcoid although, for granulomatous conditions, typically multiple topical treatments are required. I regret that I have not found benefit yet when using PDT for patients with sarcoidosis.

In a separate course on skin rejuvenation, **Prof Klaus Fritz** (Landau, Germany) observed that a variety of treatment protocols

using PDT are being reported, using various light sources, including intense pulsed lights and laser. Rejuvenating effects that are histologically and histochemically documented increase the evidence supporting the use of PDT in this indication. Compared to other procedures such as chemical peel, PDT typically needs a few sessions only and combines a highly effective cosmetic improvement with a low risk of side-effects. Tolerance of pain and immediate skin reaction following PDT still need refining to minimise discomfort to patients whilst optimising clinical benefit.

In a symposium on acne, **Dr Vincenzo Bettoli** (Ferrara, Italy) discussed the potential of PDT in acne, although pointed out that there remains no consensus on the best treatment protocol.

My attention was drawn to a study by **Dr Claudio Comacchi** (Pisa, Italy) where MAL- or ALA-PDT were evaluated in the treatment of superfluous hair in women. Results indicated PDT was as effective as laser, but that the effects were independent of skin type or hair colour and no long-term effects such as hyperpigmentation and scarring were evident, increasing the range of potential use of PDT in areas where laser therapy is more limited.

Prof Fritz also reported, in a poster, the use of PDT using ALA or MAL where the point source of light is placed subcutaneously, immediately under the lesion. Ten patients with plantar warts were treated 2-3 times, 4 weeks apart, with 9 complete responses and 1 partial response, with no recurrences over 6 months. Each treatment lasted around 30

minutes, with the low-intensity light allowing for the avoidance of pain. Although an interesting description, it certainly increases the invasiveness of PDT and also adds considerably to the hospital treatment time associated with plantar wart therapy.

In another study of the use of PDT for the treatment of recalcitrant viral warts, **Dr T V Desai** (Doncaster, UK) carried out a retrospective study of 29 patients where the average duration of the wart was 3 years. Twenty patients had plantar warts, 5 had hand warts only, and 3 had both hand and feet warts (1 had multiple facial plane warts). Two treatments with MAL-PDT were given using an Actilite[®] light, 7 days apart, with response evaluated at 3 months. In this study, 62% of patients achieved a cure following treatment, but it is noted that only 1 patient on immunosuppressant therapy achieved satisfactory improvement, suggesting the importance of the immune system in assisting the clearance for PDT in warts. The patient with the large number of facial warts achieved an excellent response and good cosmesis. The extent of lesion preparation prior to PDT was not clear, this being an important aspect of use of PDT in warts in other studies. Although these two posters offer encouragement for the use of PDT in warts, I am aware that a number of PDT practitioners have had difficulty repeating the high efficacy level reported in the literature for PDT in viral warts.

At this Congress, I was encouraged by the continuing level of interest in PDT, despite it now being considered an established therapy in the non-melanoma skin cancer field.

8th International Symposium on Photodynamic Therapy and Photodiagnosis in Clinical Practice

6-9 October, 2010
Bressanone/Brixen
Italy

by: **Prof Giulio Jori**
Padova (Padua), Italy

The 8th gathering of this already well-established Symposium, dealing with both mainstream and innovative aspects of PDT, was organised on the Bressanone/Brixen campus of the University of Padova by **Prof Herwig Kostron** (Innsbruck, Austria), **Prof David Russell** (Norwich, UK) and **Prof Giulio Jori** (Padova, Italy). The structure of the Symposium allowed for an in-depth, yet relaxed, examination and discussion of current practice, novel developments and future perspectives of the chemical, biological, biophysical and medical aspects of photodynamic applications. In particular, this year's Symposium was aimed at reviewing advances in the most traditional applications of PDT, including the treatment of tumours in different anatomical sites and a variety of dermatological diseases, the use of microscopic and spectroscopic techniques for early diagnosis of different pathologies, and novel groundbreaking developments, including pre-clinical and initial clinical studies on antimicrobial PDT, the molecular engineering of photosensitisers and carrier systems to enhance the selective targeting of tumour tissues, the introduction of nanotechnologies (**Figure 1**) into the field of PDT and the possible role of stem cells in modulating tumour response to PDT.

As usual, the response of the PDT community to the Symposium was excellent, as shown by the participation of 193 investigators and clinicians, out of which almost 70 were PhD or post-doctoral fellows, the total number of 25 plenary lectures given by eminent speakers, and the submission of 22 short communications and no less than 78 posters. Moreover, it was felt important to devote the first session of the Symposium to a PDT School, which represented a useful introduction for newcomers and highlighted recent advances for those who are already active in the field.

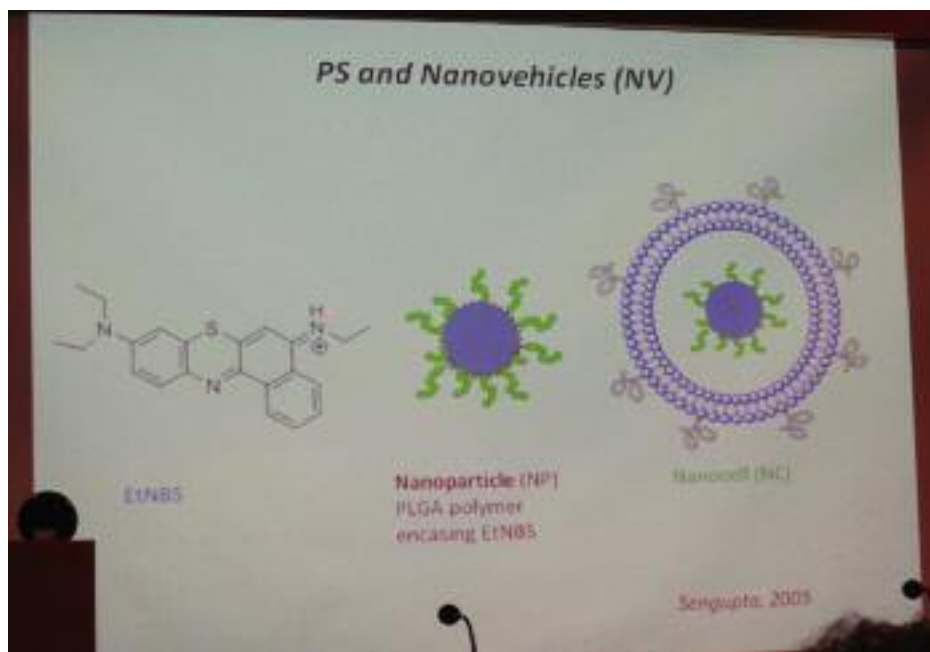


Figure 1: Schematic representation of the association of a typical photodynamic sensitiser with a multifunctional nanoparticle.

Recent work on ALA-PDT for the treatment of skin tumours and other cutaneous diseases were discussed. The basics of this specific modality were reviewed by **Dr Barbara Krammer** (Salzburg, Austria), who highlighted the efforts that are being made to understand the influencing factors and the cellular/subcellular mechanisms of this approach, including ALA import and protoporphyrin IX formation/turnover in the cell. The primary steps of ALA-PDT appear to involve the oxidative modification of proteins and lipid peroxidation by ROS formation. Various cellular effects such as an increase in intracellular calcium can be observed during or after treatment. On the molecular level, strong upregulation of stress response genes, and downregulation of genes involved in apoptosis, proliferation, survival and attachment can be found. Due to the relatively low bioavailability of the ALA molecule resulting, for example, in the poor penetration of ALA into tissue, ester derivatives (e.g. methyl aminolevulinate, MAL: Metvix®) were designed. As soon as ALA esters are taken up by the cell, they are hydrolysed into the active form by enzymes and processed in the same way as ALA. Several advantages of

MAL over ALA have been reported and some have been scientifically confirmed, including the lack of systemic effects after topical MAL-PDT and higher fluorescence after MAL application.

ALA is presently approved in many countries for topical PDT of actinic keratosis (EU, USA), and MAL for actinic keratosis, basal cell carcinoma and Bowen's disease (EU), as outlined by **Dr Alexis Sidoroff** (Salzburg, Austria). Many studies have clearly shown its efficacy, advantages and disadvantages compared to other treatment options for non-melanoma skin cancer, and there is a simple and standardised way to perform the procedure. Nevertheless, the technique of PDT application is very variable around the world, within Europe and even within individual countries. This suggests either that the 'target population' for promoting PDT in the clinical and scientific world has not really been reached, or the arguments provided in favour of PDT are not sufficient to change established conventional approaches. Although PDT has come far in dermatology, there are still lessons to learn.

However, an important option for the extension of the scope of PDT in dermat-

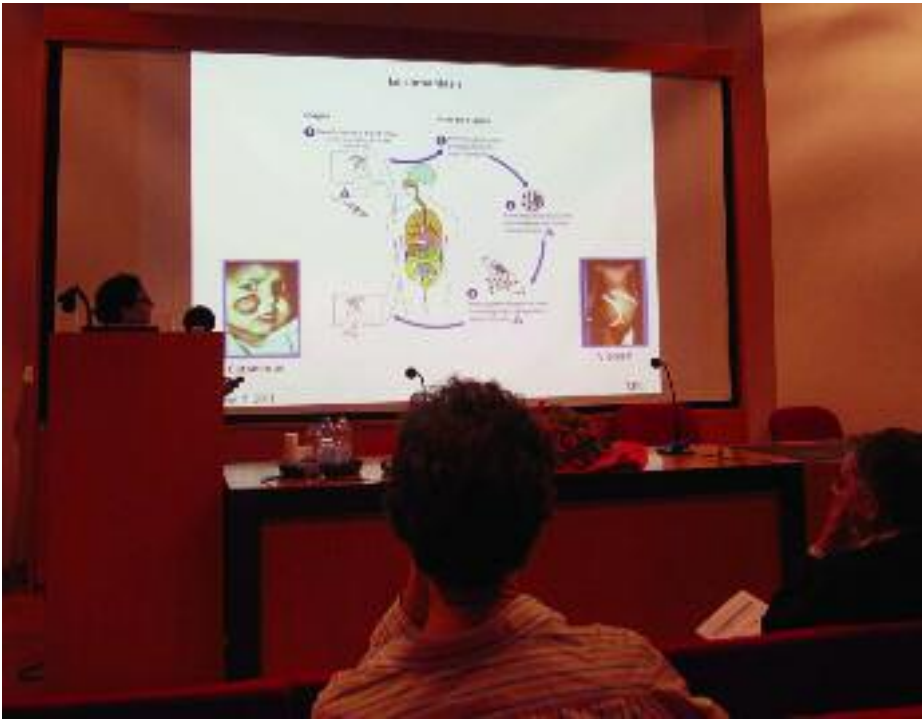


Figure 2: Dr Tayyaba Hasan illustrates the stepwise development of leishmaniasis, a disease which can now be successfully treated by PDT.

ology was illustrated by **Dr Tayyaba Hasan** (Boston, USA), who discussed the potential of PDT for killing intracellular pathogens. A large population worldwide suffers from intracellular pathogen-based infections and infectious diseases such as tuberculosis, leprosy, filariasis and leishmaniasis (**Figure 2**). The research carried out in Dr Hasan's laboratory, using appropriate animal models, opens the possibility to extend photodynamic processes to the destruction of intracellular pathogenic agents by applying the photosensitiser either systemically or loco-regionally.

One aspect which can deeply affect the efficacy and reproducibility of PDT treatment, especially in the treatment of cutaneous diseases, is light dosimetry. This issue was critically addressed by **Dr Harry Mosley** (Dundee, UK), who emphasised how measurement of the light dose delivered to tissue is a much-neglected aspect of PDT. As a consequence, the outcome of PDT treatments is often difficult to predict. He examined the key aspects of dosimetry in a clinical setting, both from a theoretical and a practical perspective. The traceability of the measured quantity is often neglected and, as a result, several studies have been carried out and reported with quite erroneous radiometric values. An apparently reliable approach for measuring the light dose within a tissue, using a newly developed Monte Carlo model, was described and shown to suggest the use of generally longer irradiation times. A novel aspect of this simulation is the ability to demonstrate

fluorescence on the surface and identify the source of this from within the tissue.

One major field in oncology where PDT can hopefully lead to significant advancements is in treating brain tumours (**Figure 3**). This was the subject of in-depth discussions in an ad hoc session, co-ordinated by Prof Kostron with the participation of **Dr Sadao Kaneko** (Sapporo, Japan), **Dr Lothar Lilge** (Toronto, Canada), **Dr Herbert Stepp** (Munich, Germany), **Dr Frederic Leblond** (Hanover, USA) and **Dr S Shliakhtsin** (Minsk, Belarus). Prognosis of malignant brain tumours is generally very poor, but approaches which are being currently explored suggest

that PDT can significantly improve the therapeutic perspectives; such approaches include stereotactic interstitial PDT without tumour resection, the combination of fluorescence-guided resection and laser irradiation (based on ALA-promoted formation of protoporphyrin IX), and the use of erythropoietin as a neuroprotectant in order to reduce the responsiveness of normal neurons and glial cells to photodynamic treatment. Intriguing long-term survival has been observed in a few patients who received intraoperative PDT after i.v. administration of Photolon, a novel chlorin-based photodynamic agent.

The principles, scope and potential of laser-induced fluorescence (LIF) for early tumour detection and support to PDT were very clearly detailed by **Dr Katrina Svanberg** (Lund, Sweden). LIF can be used for monitoring the biomolecular changes accompanying the transformation from normal to dysplastic and cancer tissue before structural alterations are seen at a later stage; signals arising from endogenous chromophores in the tissue alone, or enhanced by exogenously administered tumour-seeking substances can be utilised. The technique is non-invasive and gives the results in real time. LIF can be applied for point monitoring or in an imaging mode for larger areas, such as the vocal cords or the portion of the cervical area. Lastly, the LIF data can be integrated by a new method, by which free gas (oxygen or water vapour) in the human sinus cavities is detected. The technique is based on gas absorption spectroscopy in scattering media. The method can also be used to study the gas exchange between the nasal cavity and the different sinuses in the facial region. Additional pathways for improving the fluorescence

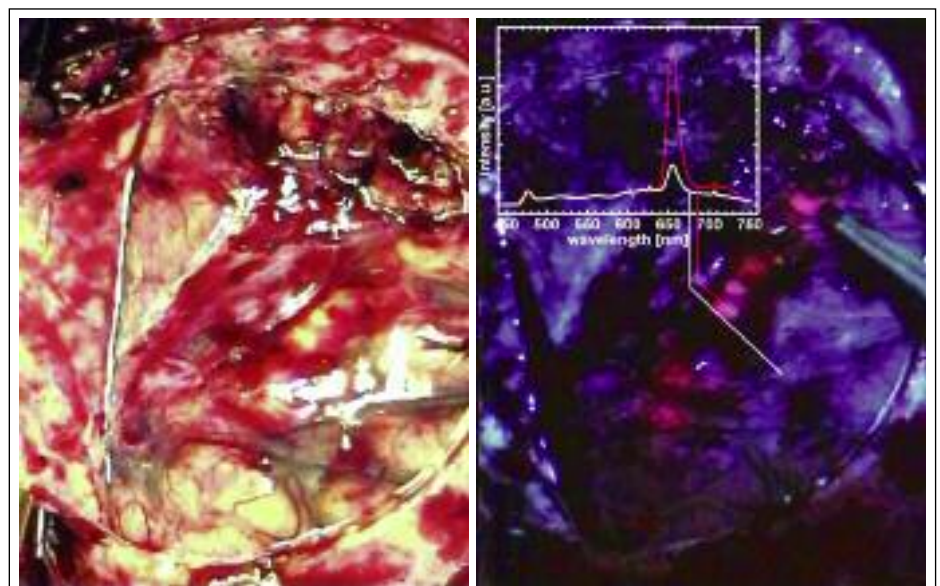


Figure 3: Porphyrin fluorescence for the detection and laser-guided resection of a brain tumour.

observations are opened by the emerging simultaneous incorporation of time-resolved and spectral-resolved imaging (**Dr Angelika Rück**, Ulm, Germany). The concerted application of a number of optical techniques, spanning from elastic scattering spectroscopy and confocal microscopy to fluorescence and differential path length spectroscopy, provides refined insights into early cancer so that PDT can be successfully utilised in the treatment of head and neck malignancies, with advantages for function and aesthetics (**Dr Colin Hopper**, London, UK). Dr Hopper, in collaboration with **Dr Kristian Berg** (Oslo, Norway), additionally presented the first positive results of Phase I/II clinical trials based on the application of the photochemical internalisation strategy, which had so far been only tested at a pre-clinical level.

PDT has been expanding into a broad array of medical applications beyond cancer diagnosis and treatment. Amongst these non-oncologic applications, PDT-mediated antimicrobial therapy is promising, with encouraging pre-clinical and initial clinical data. Generally, the focus of antimicrobial PDT has been in localised treatment of infections caused by extracellular pathogens. This topic was discussed by myself, and I also organised a session, involving contributions from **Dr Michael Hamblin** (Boston, USA) on the development of appropriate animal models for optimising the PDT of infectious diseases, **Prof Michael Wilson** (London, UK) on the promising perspectives opened by the introduction of

nanotechnologies in this specific area, and **Prof Stan Brown** (Leeds, UK), who critically examined the results of initial clinical trials aimed at promoting the healing of bacterially colonised chronic leg ulcers and diabetic foot ulcers using PDT with selected phenothiazinium derivatives. The treatment appeared to be safe and effective in reducing bacterial loads, while there was a clear trend towards healing in the treatment arms compared with a placebo arm. Lastly, I explained how photodynamic control of microbial populations can be very useful also in the environmental field, e.g. for the disinfection of waters with a large pathogen load, or the prevention of malaria.

A subject which was debated in depth was the engineering of photosensitisers to improve tumour targeting. As described by Prof Russell, currently used photosensitisers generally yield tumour targeting in a 2-3:1 ratio to peritumoural tissues. Improving this value could reduce the dose required for an efficacious PDT outcome and minimise undesired side-effects. The most promising means to achieve a better targeting include the association of photosensitisers with antibodies or aptamers, as well as with peptides, sugars or folic acids, and the development of multifunctional nanoparticles as carriers. The strategy, based on the use of peptides and folic acid, was exemplified by the work of **Dr M Barberi-Heyob** and **Dr Céline Frochot** (Nancy, France), while the attachment of photosensitisers to nanoparticles was examined in detail during the session organised by

Prof Russell, with the participation of Dr Barberi-Heyob, Prof Wilson, **Dr Y Zang** (Singapore) and **Dr Hong Zhang** (Amsterdam, The Netherlands): the nanoparticle-bound photosensitisers are often endowed with a greater molar extinction coefficient and a higher quantum yield of singlet oxygen generation and lead to a more selective tumour targeting. One peculiar development of the adoption of nanotechnological innovations in PDT is the implementation of photonic platforms. The construction details and preliminary tests of such a platform for the diagnosis and therapy of cancer have been outlined by Dr Zhang. The approximately 20nm platform is based on rare earth ion-doped nanoparticles, and performs dual functions, i.e. fluorescence diagnosis and therapy, which are switchable by external photons: luminescence of rare earth ions excited by a near-IR laser via a multi-photon absorption (up-conversion) process and singlet oxygen generated by the transfer of excitation energy of rare earth ions to a photosensitiser are the backbone of this novel concept.

New ideas of great potential impact were presented by **Dr P Selbo** (Oslo, Norway), who emphasised the advantages associated with the properties of a few PDT sensitisers, including Photofrin, protoporphyrin IX, benzoporphyrin derivative and hypericin, to be substrates of the ATP-binding cassette transporter ABCG2, a cancer stem-cell marker associated with chemoresistance. Thus, Dr Selbo proposed an interesting pathway leading to the eradication of cancer stem cells, an achievement which could substantially increase the chances of obtaining a complete response of the tumour and a long-term disease-free survival.

The Symposium was followed by a session organised by the **European Platform for Photodynamic Medicine** (EPPM), presently chaired by Prof Kostron. Presentations and related discussions during this session were largely focused on the building of European-based networks of basic and clinical PDT open to the participation of investigators and clinicians, the strategies to reinforce the interaction between PDT centres and industries, and the steps to be undertaken in order to move PDT into routine clinical practice for selected diseases. The possible role of nanotechnologies in PDT and the current openings in the EU committees for PDT were discussed by **Dr Patrick Boisseau** (Grenoble, France).

The Symposium ended with a unanimous recommendation to the organisers to hold this meeting again in 2012.



Figure 4: The outdoor poster session, which was held in the yard of the Symposium venue, with a buffet lunch, and was well-attended and appreciated.



Prime Time PDT

An international roundup of
PDT-related papers and publications

Increased Cutaneous Oxygen Availability by Topical Application of Hydrogen Peroxide Cream Enhances MAL-PDT

R Manifold and C Anderson 2011 *Arch Dermatol Res* **February 3**
(E-Pub ahead of print)

It has been demonstrated that the effectiveness of PDT is affected by the local availability of oxygen. In this Australian study, 40 healthy volunteers received methyl aminolevulinate (MAL)-PDT using a red light source to the inner forearms. In order to reduce skin oxygen availability, blanching pressure was applied during illumination, using a plastic slide. To reverse this effect, hydrogen peroxide cream was applied under the pressure slide immediately prior to illumination.

The authors aimed to measure the photodynamic reaction (PDR) resulting from either reduction or increase in skin oxygen availability. Erythema at 1, 5, 24 and 48 hours following illumination was assessed both visually and by laser Doppler perfusion imaging (LDPI). Reduction by pressure of skin oxygen availability reduced the number of subjects showing any erythema (and thus PDR) at any time point, compared to a PDR control site. Conversely, use of the hydrogen peroxide cream increased the number and duration of measured erythema, compared to the control site. The authors suggest that hydrogen peroxide cream could be usefully added to PDT protocols and call for further trials to be undertaken.

Chondrodermatitis Nodularis Chronica Helicis and PDT

M Pellegrino *et al* 2011 *Dermatol Ther* **24** 144-147

Chondrodermatitis nodularis chronica helicis (CNCH: also known as Winkler's disease) is a painful and fairly frequent disorder affecting the ears of mainly middle-aged men. The standard therapy is surgery, although a wide number of less invasive therapies have been proposed. In this Italian case study of two patients with CNCH, the authors used 20% ALA-PDT with occlusion for 3 hours and illumination at 635nm for 20 minutes (70J/cm²). The lesions were reduced in size and the CNCH-associated pain stopped after a few weeks. The authors suggest that PDT could be a useful alternative in CNCH patients, especially those with contraindications for surgery.

Daylight-Mediated PDT with MAL in Multiple AK: Randomised Multi-Centre Study

S Wiegell *et al* 2011 *Brit J Dermatol* **January 11**
(E-Pub ahead of print)

Daylight-mediated PDT offers an interesting alternative to illumination in the clinic and may also reduce the amount of

pain experienced by patients in the clinical setting. But how long is an effective 'dose' of solar radiation? In this Swedish/Danish randomised, multicentre study, daylight exposure times of 90 minutes and 150 minutes were compared, using MAL-PDT in a total of 120 patients with multiple thin actinic keratoses (AK) of the face and scalp (1572 lesions).

The lesions were gently prepared, then a sunscreen of factor 20 was applied, followed by MAL over the whole treatment area. The patients then left the clinic for their allotted time. Daylight exposure was measured, using a wristwatch dosimeter, and patients scored their own pain sensation.

The mean lesion response rate at 3 months was 77% for the 90-minute sun-irradiation group, versus 75% for the 150-minute group (NS). The mean overall effective light dose was 9.4J/cm² and daylight exposure varied from 35-365 minutes. There was no correlation between response rate and effective daylight dose, exposure duration, treatment centre, or time of day/year. Pain scores were very low (Maximum 1-3) and the treatment was well tolerated. The authors conclude that daylight-mediated MAL-PDT is an effective, convenient and almost pain-free option for patients with thin multiple AKs, with uniformly high response rates in the period June-October, in Nordic countries.

Factors Related to Pain During Routine PDT

I Miller *et al* 2011 *J Eur Acad Dermatol Venereol* **January 17**
(E-Pub ahead of print)

Pain experienced by patients is a limiting factor for PDT. This Danish descriptive study of 301 patients who underwent routine PDT examined both the frequency of pain felt and the interventions used to limit it. Retrospective data were available from a total of 983 PDT treatments on 579 lesions. Of these, 56% did not require intervention at all, 35% required the use of cold water sprays and 9% required a pause in treatment or use of nerve blockers. Although larger lesions were associated with greater frequency of intervention, they were not associated with a greater degree of intervention. Lesions on the scalp/forehead required both greater frequency of intervention and the highest level of pain-relieving intervention, but the authors found no significant association between intervention and diagnosis, pre-treatment, gender or age.

Herpes Simplex Reactivation and PDT

S Nobbe *et al* 2011 *Photodermatol Photoimmunol Photomed* **27** 51-52

The authors report a case of an 81 year-old man who experienced a reactivation of herpes simplex virus which was localised to the area treated for PDT of AK (right forehead). Antiviral prophylaxis was given and further sessions of PDT were delivered without further viral reactivation. The treatment was successful and well tolerated.

Continued on page 8

Prime Time PDT

Continued from page 7

Red Versus Blue Light Sources in MAL-PDT for Photodamage

M Palm and M Goldman 2011 *J Drugs Dermatol* 10 53-60

PDT with MAL has recently received FDA approval in the USA, but the market has long been associated with ALA. As ALA-PDT is usually conducted with blue light illumination and MAL-PDT usually involves a red light source, the authors designed a prospective, single-centre study to investigate the safety and efficacy of both red and blue light illumination with MAL in photorejuvenation.

The study involved 18 adults with moderate-to-severe photodamage of the head or upper trunk. The patients received split-area MAL-PDT, using either red or blue light, to allow comparison of the two illuminations in each patient. Most of the patients also received either pulsed-dye laser (PDL) or intense pulsed light (IPL) for photoactivation. The sites were assessed with photography and patient and physician scoring at 0, 2, 7 and 30 days after treatment.

There were no statistically significant differences in efficacy between the two light sources. The treatments were well tolerated and side-effects mild, with only mild erythema persisting for longer than 7 days. The authors conclude that MAL-PDT with either red or blue light is effective in the treatment of photodamage, in particular AK and pigmentation.

Calendar of Events 2011

March 24-26, Monte Carlo, Monaco
9th Anti-Aging Medicine World Congress

Contact: EuroMediCom
Tel: +33 (0) 1 56 83 78 00 Fax: +33 (0) 1 56 83 78 05
Website: www.euromedicom.com/amwc-2011

April 14-17, Carlsbad, Czech Republic
8th Spring Symposium of the European Academy of Dermatology and Venereology (EADV)

Contact: Jasta Travel Agency s.r.o.
Tel: +420 602 322 900 Fax: +420 267 913 943
e-mail: info@eadvcarlsbad2011.org

April 19-21, Dubai, UAE

Dubai Derma 2011
Contact: Index Conferences & Exhibitions
Tel: +971 4 362 4717 Fax: +971 4 362 4718
e-mail: index@emirates.net.ae
Website: www.dubaiderma.com

May 10-14, Innsbruck, Austria
13th World Congress of the International Photodynamic Association (IPA)

Contact: pco Tyrol Congress
Tel: +43 512 575 600 Fax: +43 512 575 607
Website: ipa2011@come-innsbruck.at

May 24-29, Seoul, South Korea
22nd World Congress of Dermatology (including World Photodermatology Day)

Contact: WCD Secretariat
Tel: +822 3476 7700 Fax: +822 3476 8800
e-mail: registration@wcd2011.org
Website: www.wcd2011.org

October 20-24, Lisbon, Portugal
20th Congress of the European Academy of Dermatology and Venereology (EADV)

Contact: Mundiconvenius
Tel: +351 213 155 135 Fax: +351 213 558 002
e-mail: info@eadvlisbon2011.org



Are you receiving *Clinical Photodynamics*?

If this is not your personal copy of *Clinical Photodynamics* and you would like to receive regular copies directly, free of charge, then please either copy and complete this form and post it, in an envelope, to our Editorial Office or fax or e-mail your details to us (see opposite).

Title:

First Name/Initials:

Surname:

Post held:

Workplace:

Address for mailing:

Country:

Postal/Zip Code:

e-mail:

PLEASE RETURN THIS FORM TO: Eurocommunica Limited
Caxton House, 51 Barnham Road, Barnham, West Sussex PO22 0ER, UK
FAX: +44 (0) 1243 555043 E-MAIL: EUROCOMMUNICA@sky.com