

# Clinical Photodynamics

*In Dermatology*

An International Newsletter for PDT and FD in Clinical Practice

## Editorial

This issue has a strong focus on the management of precancerous and cancerous skin lesions in transplant recipients, who tend to be heavily immunosuppressed as a measure to prevent rejection of their transplanted tissue. As a result, transplant patients run a 100-fold increased risk of developing non-melanoma skin cancer compared to the general population. The main article gives a review of the history and current thinking on this growing problem and various measures are discussed to control it. Additionally, Günther Hofbauer and Andreas Serra share their practical experience with us and highlight the work of SCOPE. We also carry a report on the recent IPA meeting in Seattle.

Looking forward to 2010, the Euro-PDT Conference will take place in Monte Carlo (11-13 March) and EADV is to be held in

Göteborg (6-10 October). Subjects expected to be covered include the importance of vitamin D formation in the skin. Recent studies have revealed that patients undergoing phototherapy for psoriasis have a higher bone density. It might be that small amounts of UVB have a net positive effect for the human body.

Additionally, acne treatment continues to accumulate interesting data. Camilla Hörfelt and co-workers from Göteborg have demonstrated a beneficial effect of PDT on acne. Also, a beneficial effect with the use of visible light may be seen. For the future, PDT in mild to moderate acne is likely to be a suitable alternative to current therapies, especially since bacterial resistance is an increasing problem.

**Ann-Marie Wennberg**, Göteborg, Sweden

## PDT in the Immunosuppressed Patient

by:

**Prof Ann-Marie Wennberg**  
Consultant Dermatologist  
Göteborg, Sweden

In recent years, the ability to successfully transplant human organs has revolutionised the care of patients with severe kidney, liver, lung and/or heart disease. Previously, if these patients didn't die from the disease or from complications, they could face years of chronic illness, requiring regular intervention such as kidney dialysis. Many of these patients can now be saved by organ transplantation and lead a remarkably normal life. In addition, the cost to society has been reduced: even though transplantation is an extremely expensive option, the net cost to society is less than the long-term treatments of the underlying disease. Moreover, as the management of transplant recipients has improved, post-transplant survival has increased: more patients are living longer with a functioning

**Figure 1: Six cancers with greatly increased rates of occurrence in organ transplant patients and associated viral oncogenesis.**

Cancer	↑ Rate	Virus
Non-Hodgkin's lymphoma	50-fold	EBV
Kaposi's sarcoma	500-fold	HHV8
Vulval carcinoma	100-fold	HPV
Hepatocellular carcinomas	40-fold	HBV
Cervical neoplasia	15-fold	HPV
Cutaneous squamous cell carcinoma (SCC)	110-fold	?HPV

graft. However, the process is not perfect and has led to the emergence of novel challenges for clinicians.

### CARCINOGENIC SIDE-EFFECT OF LONG-TERM IMMUNOSUPPRESSION

The profound immunosuppression that is necessary to prevent rejection of the grafted organ has its own set of potentially problematic side-effects, some of which can occur

relatively soon after transplantation, whilst others present a longer term risk to survival.

One of these side-effects is the increased risk of malignancy: for most cancers, transplant recipients have a 2- to 5-fold greater risk of development, but for some viral-related cancers, the risk is considerably greater (**Figure 1**). Furthermore, some of the earlier immunosuppressive agents have been found to be actively carcinogenic with long-term use. Naturally, for dermatologists, the skin

### Editorial Board

**Prof Peter Foley** Melbourne, Australia  
**Dr Sigrid Karrer** Regensburg, Germany  
**Dr Colin Morton** Stirling, Scotland  
**Prof Ann-Marie Wennberg** Göteborg, Sweden

### In this Issue

**PDT in the Immunosuppressed Patient** 1  
**Dermatology Meets Nephrology: Skin Care in Renal Transplant Recipients** 5  
**SCOPE** 6  
**12th World Congress of the International Photodynamic Association (IPA)** 7

malignancies and their long-term effects are of greatest significance.

The link with viruses is intriguing. It is thought that some papilloma viruses, specifically the  $\beta$ -papillomaviruses, may play a co-factorial role in skin cancer development in conjunction with the mutagenic effects of UV radiation. If it can be established which of these  $\beta$ -papillomaviruses are 'high-risk', then it may be possible to develop prophylactic vaccines in the future. However, at present, the role of these viruses in transplant-related skin cancers is unproven. Certainly, transplant recipients tend to have a greater number of warts and, in some patients, the degree of wart proliferation is spectacular, causing severe disfigurement that requires radical surgical intervention<sup>1</sup>.

The link between immunosuppression and increased risk of skin cancer was, not surprisingly, first identified in the early 1980s in Australia, where the combination of high rates of sun exposure and a large population of transplant recipients enabled significant data to be collected via the ANZDATA Registry. The risk of development of skin cancer rose with increasing time after transplantation (**Figure 2**). Other Western countries then began to observe the same higher incidence of skin cancers in their own transplant populations<sup>2,3</sup>.

## MANAGEMENT

As the skin cancer workload began to become apparent, many transplant centres found it useful to co-operate with their dermatological colleagues to establish a dedicated skin clinic for transplant recipients. Candidates for transplantation could now be assessed for their likelihood of developing skin cancer prior to their operation and then routinely followed-up post-transplantation<sup>4</sup>.

The risk factors are largely the same as for development of skin cancer in the general

population: fair skin, outdoor employment and/or leisure pursuits, time spent in an area of high sun exposure, etc. However, skin cancers are also found in patients with a dark skin tone, so they will still require regular monitoring. A careful and thorough visual inspection by an experienced dermatologist should be undertaken and a high index of suspicion employed for any skin lesion seen. This is especially important, as the clinical picture is not always typical: what at first glance appears to be a wart may well be a premalignant skin lesion. The other factor influencing development of skin cancers is age at transplantation: the older a patient is at the time of transplantation, the sooner they will start to develop skin cancers.

Skin cancers in the transplant population tend to be more aggressive than their counterparts in the general population: they can develop with dramatic speed and, as indicated earlier, sometimes with an unusual appearance. Also, patients will usually develop several lesions over time and a smaller sub-set (approximately 9% of patients) will develop multiple lesions that will account for something like 80% of all lesions seen in the local transplant population<sup>5</sup>. There have been several attempts to try to identify these high-risk members of the transplant population for development of NMSC. A high level of immunosuppression has been indicated as a significant risk factor.

Field change (also known as field cancerisation) is a concept whereby carcinogenesis is occurring at different rates in multiple sites in sun-exposed skin, with both visible clinical disease and subclinical lesions present. Actinic keratoses (AKs) are thought to be a precursor for SCC and so their presence is the first visible indicator of skin dysplasia. The presence of AKs is highly associated with

risk of SCC and basal cell carcinoma (BCC) development. For this reason, AKs are often used as surrogate endpoint biomarkers in skin cancer prevention studies.

Transplant recipients should be targeted for thorough and regular education about photoprotection. Generally, the same advice applies to them as for the general population, but it should be emphasised that they are much more sensitive to the hazardous effects of sunlight. Therefore, when going outside, hats and thick clothing should be worn and high protection factor sunblock creams used on exposed areas of skin, even on cloudy days. Patients should be encouraged to report any changes in their skin to their clinicians at the earliest opportunity.

## TREATMENT OPTIONS

Treatment is divided into two aspects: therapy for existing lesions and longer term prevention/minimisation of recurrence. In recent years, much interest has been focused on the reduction of future lesions, and PDT is well-placed to offer both excellent treatment of existing lesions and the possibility of prevention of recurrence.

The advice for treatment of skin malignancies in transplant recipients is based upon the same guidelines as for the general population. However, the treatments given are more often of a multidisciplinary nature, more aggressive and with more regular follow-up. Immunosuppression should be reduced if possible, although patients (and their transplant physicians) are usually more concerned about the risk of organ rejection than any potential reduction in skin lesions in the future and are therefore reluctant to alter an immunosuppressive regimen that they have received for years and are comfortable with. This has been a major problem for recruitment into several clinical trials, such as RESCUE, which have aimed to investigate the possibilities for reduction in cancers by lowering of immunosuppression or conversion to a newer, less carcinogenic, immunosuppressive agent. Sirolimus (also known as rapamycin) is a novel immunosuppressive agent that also displays anti-carcinogenic properties, which may offer considerable benefits in long-term immunosuppression in the future<sup>6</sup>.

For melanomas and SCCs, surgical excision, with sentinel node biopsy where possible, is the therapy of choice. Because of the aggressive nature of these cancers in transplant recipients, the operation should be carried out as soon as possible after detection. For BCCs and AKs, surgery may be less urgent, and less invasive treatments such as PDT can be given, but the lesions will require continual monitoring.

Systemic low-dose retinoids have been

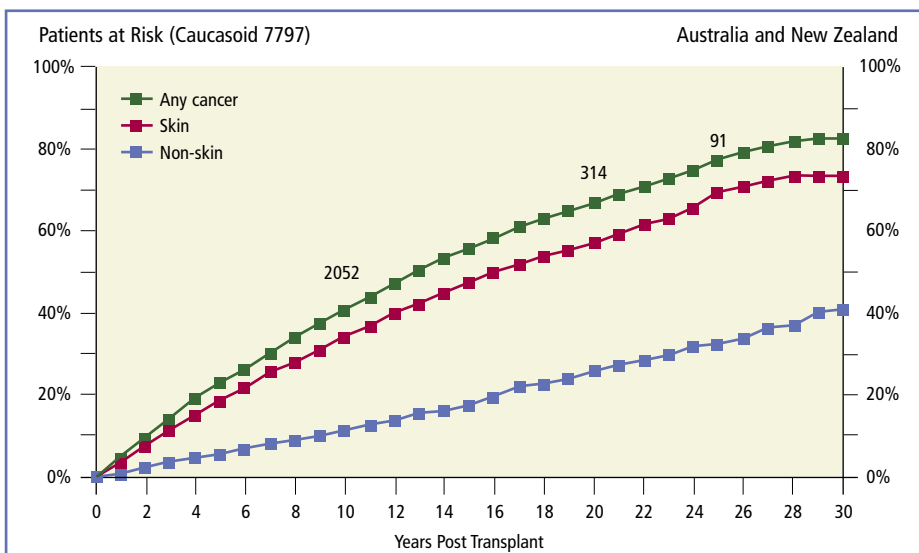


Figure 2: Risk of cancer post-transplantation, 1965-2001 (ANZDATA Registry).

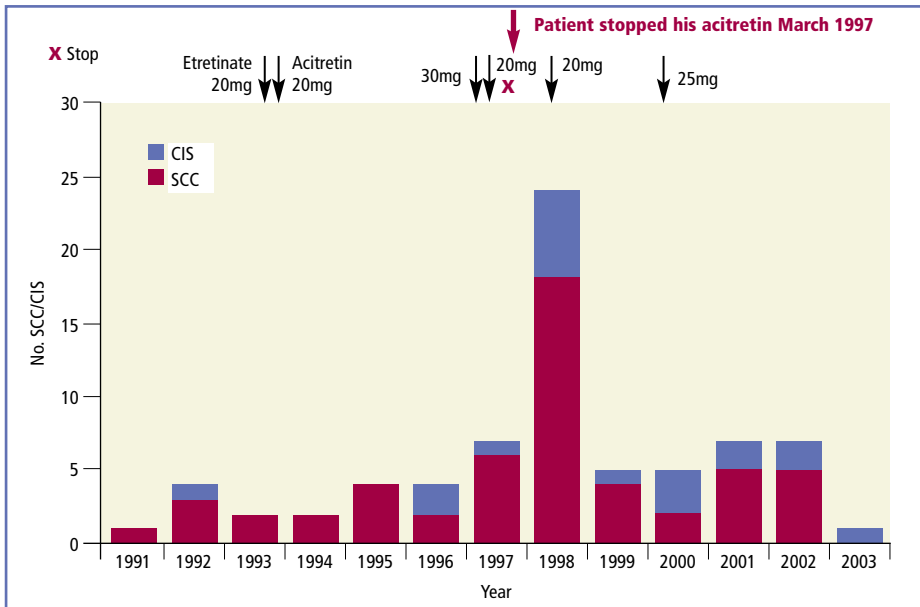


Figure 3: Rebound of SCC when retinoids are stopped (Dr C Proby, personal communication).

used successfully in reducing the development of new skin lesions, often for 3 years and longer, irrespective of age, tumour burden and time after transplantation. However, efficacy appears to decline thereafter<sup>7</sup>. Continuous treatment is necessary to maintain the chemoprotective effect: cessation leads to a return of lesions (Figure 3). Retinoids are well-tolerated in low doses and may offer a useful adjunct for metastatic disease. Further studies are required to determine how beneficial their role is.

Topical treatments include imiquimod, 5-

fluorouracil (5-FU), cryosurgery and PDT. Imiquimod is an immune response modifier which, when applied as a 5% cream, has demonstrated an effect on AKs and field change. It is more effective when used on the head and neck than on acral sites such as the back of the hand or forearm<sup>8</sup>. This may relate to difficulty with penetration through hyperkeratotic skin. Not all patients respond to imiquimod and, in transplant recipients, it may be necessary to use daily applications, rather than 3 or 5 times per week<sup>8</sup>. 5-FU is a longstanding topical treat-

ment for AKs, exercising a cytotoxic effect in sun-damaged skin cells. With both of these treatments, patient compliance is a major concern for long-term therapy and the repeated applications that are necessary.

In order to avoid such compliance problems, 'one-shot' treatments can be given. These include local surgical excision, cryosurgery, PDT and possibly radiation. Using these treatments, compliance problems are very rare. However, surgery is particularly disfiguring and can be very complex or impractical in certain sites such as the face and areas of field cancerisation. Cryotherapy, too, can cause unsightly skin discolouration and is unsuitable for treatment of large areas.

### TOPICAL PDT FOR THE TREATMENT AND PREVENTION OF RECURRENCE

Topical PDT has major advantages over other therapies in terms of cosmetic outcome, compliance, treatment of field cancerisation and ability for repeat treatments over time.

The efficacy of PDT with methyl aminolevulinic acid (MAL: Metvix<sup>®</sup>) in treating premalignant skin lesions in transplant recipients is comparable to that in the general population and is well documented. Dragieva *et al*<sup>9</sup> enrolled 17 transplant recipients with 129 mild to moderate AKs in a prospective, randomised, double-blind, placebo-controlled study. Two areas on each patient received either MAL-PDT or placebo (2 treatments, 1 week apart). In 13 patients,

Table 1: A scheme for the management of non-melanoma skin cancers in organ transplant recipients (adapted from Ulrich *et al* 2009<sup>13</sup>).

Actinic Keratosis (AK) Management		Invasive Squamous Cell Carcinoma (SCC) Management		Basal Cell Carcinoma (BCC) Management	
Mild (< 5 AK)	<ul style="list-style-type: none"> <li>- Sun-protective measures</li> <li>- Lesion-adapted destructive therapies</li> <li>• Cryotherapy</li> <li>• CO<sub>2</sub> laser</li> <li>• Electrocautery/Curettage</li> <li>- <b>Consider field-adapted therapies</b></li> </ul>	Clinically less aggressive <ul style="list-style-type: none"> <li>• Small size</li> <li>• Slow growing</li> <li>• Well-defined margins</li> <li>• Non-ulcerated</li> </ul>	<ul style="list-style-type: none"> <li>- Sun-protective measures</li> <li>- Treatment of field cancerisation</li> <li>- Complete removal (consider Mohs' micrographic surgery)</li> <li>- Systemic therapies</li> <li>Revision of immunosuppression</li> </ul>	Superficial (sBCC)	<ul style="list-style-type: none"> <li>- Sunprotective measures</li> <li>- Therapies for superficial BCC</li> <li>• 5-Fluorouracil</li> <li>• 5% Imiquimod cream</li> <li>• <b>Photodynamic therapy</b></li> <li>- Complete removal (consider Mohs' micrographic surgery)</li> </ul>
Moderate (> 5 AK in < 100 cm <sup>2</sup> area)	See above plus: <ul style="list-style-type: none"> <li>- <b>Field cancerisation therapies</b></li> <li>• 3% diclofenac in 2.5% hyaluronic acid gel</li> <li>• 5% Imiquimod cream</li> <li>• 5-Fluorouracil</li> <li>• <b>Photodynamic therapy</b></li> <li>- <b>Consider revision of immunosuppression</b></li> </ul>	Clinically aggressive <ul style="list-style-type: none"> <li>• Large size + location</li> <li>• Rapid growth</li> <li>• Poorly defined margins</li> <li>• Ulcerated</li> </ul>	See above plus: <ul style="list-style-type: none"> <li>- <b>Consider sentinel lymph node biopsy ± dissection</b></li> <li>- <b>Consider systemic retinoids</b></li> </ul>	Nodular and other non-sBCC	See above plus: <ul style="list-style-type: none"> <li>- <b>Consider revision of immunosuppression</b></li> </ul>
Severe (> 15 AK / >100 cm <sup>2</sup> )	See above plus: <ul style="list-style-type: none"> <li>- Systemic therapies</li> <li>• Revision of immunosuppression</li> <li>• Systemic retinoids</li> </ul>	Histologically aggressive <ul style="list-style-type: none"> <li>• Poorly differentiated</li> <li>• Invading subcutaneous fat</li> <li>• Perineural invasion</li> </ul>	See above plus: <ul style="list-style-type: none"> <li>- Sentinel lymph node biopsy ± dissection</li> <li>- <b>Consider systemic retinoids</b></li> </ul>		

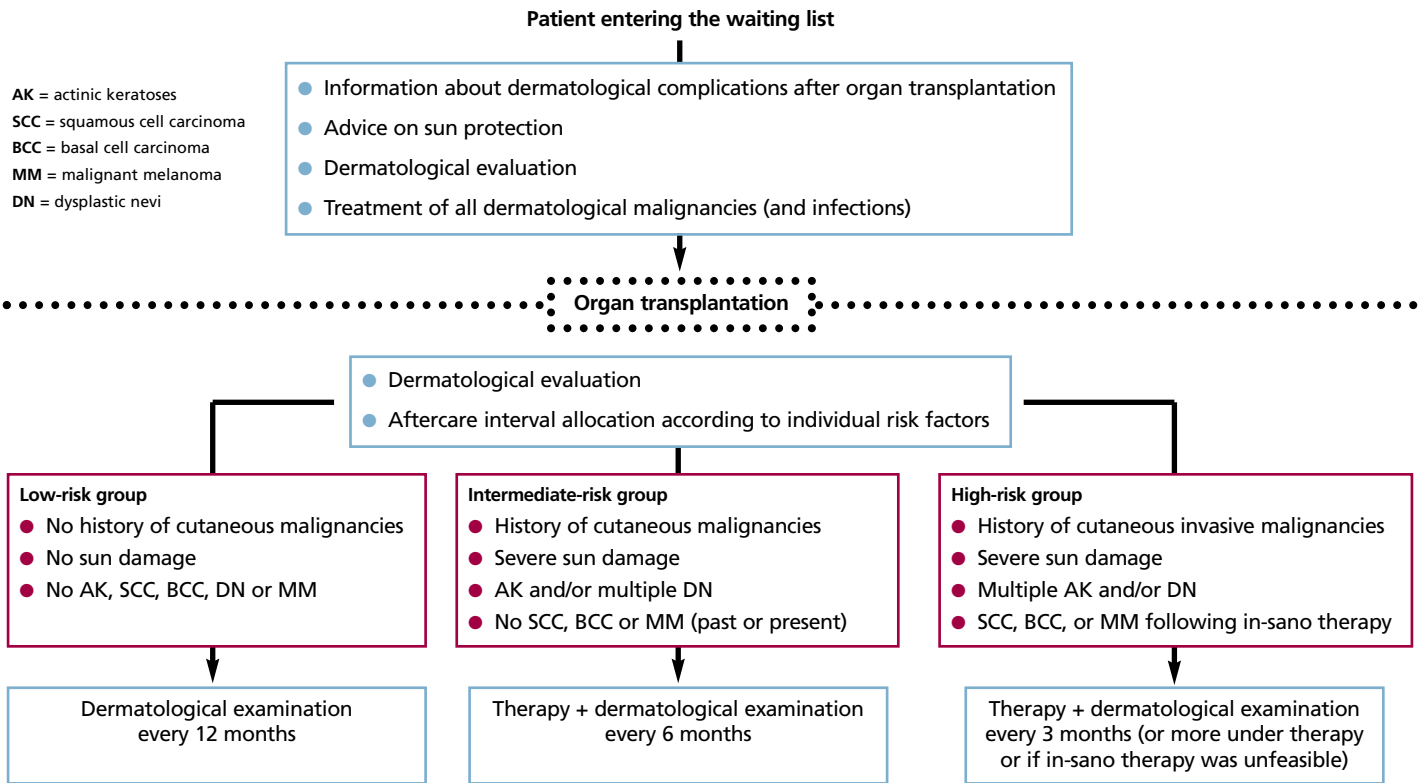


Figure 4: A scheme for dermatological evaluation and aftercare in organ transplant recipients (adapted from Ulrich *et al* 2009<sup>13</sup>).

the MAL-PDT treated areas showed clinical clearance at 16 weeks post-treatment, with a partial response in 3 further patients. No placebo-treated area showed any reduction in size or number of AKs.

Perrett *et al*<sup>10</sup> directly compared the effects of 5-FU cream with MAL-PDT in 8 transplant recipients. Each patient received 5-FU treatment (twice daily for 3 weeks) to an area of skin dysplasia and MAL-PDT (2 cycles, 1 week apart) to a comparable site. At all timepoints in the study (1, 3 and 6 months post-treatment), MAL-PDT was more effective than 5-FU in achieving complete resolution of lesions ( $p = 0.02$ ). The mean lesional area reduction was also greater with MAL-PDT (100% for MAL-PDT, versus 79% for 5-FU). MAL-PDT also gave superior cosmetic outcome and was preferred by patients.

The ability of PDT to prevent or delay the occurrence of new skin lesions was examined by Wulf *et al*<sup>11</sup>. A total of 27 transplant recipients received MAL-PDT to a 5cm diameter area of skin, with a similar area left untreated. The time to occurrence of the first new skin lesion was significantly longer in the PDT-treated areas (9.6 months versus 6.8 months;  $p = 0.034$ ). One year after treatment, 62% of the treated areas were free from new lesions, compared to 35% of the control areas, indicating that MAL-PDT was a promising preventative treatment against new skin lesions in this patient group.

Recently, an open, randomised, multicentre study<sup>12</sup> examined the use of topical MAL-PDT in the prevention of development of new skin

lesions by regularly repeated field therapy. A total of 81 transplant patients with 889 existing lesions were treated with field treatment MAL-PDT on a 50cm<sup>2</sup> area of skin. An initial treatment of 2 MAL-PDT sessions, 1 week apart, was followed by further MAL-PDT sessions at 3, 9 and 15 months. This area was compared to a similar sized area on each patient that was given lesion-specific therapy only, mainly cryotherapy (83%). All visible lesions were given lesion-specific treatment in both MAL-PDT-treated and control areas at 21 and 27 months.

At 3 months, MAL-PDT significantly reduced the occurrence of new lesions (65 lesions versus 103 lesions;  $P = 0.01$ ). This was mainly in the reduction of AKs (46% reduction;  $P = 0.006$ ). By 27 months, however, this difference had ceased to be significant. Hypopigmentation, assessed by the investigator, was less evident in the MAL-PDT-treated areas compared to the control areas. The authors concluded that regular field treatment with MAL-PDT has the potential to prevent AKs in transplant recipients.

In a recent review of the management of skin cancer in organ transplant recipients, Ulrich *et al*<sup>13</sup> proposed a scheme for patients with NMSC according to type and severity of disease (Table 1). They also set out an algorithm for dermatological evaluation and aftercare of these patients (Figure 4).

## CONCLUSIONS

Topical PDT is well established as a safe and effective treatment option for appropriate

skin lesions in transplant recipients. The treatment offers excellent cosmesis and has a high patient satisfaction rate. Furthermore, topical PDT offers the potential for multiple field treatments over time with the aim of reduction of development of new skin lesions, although further studies are required to confirm this result.

## References

- Boyle *et al* 1984 *Lancet* (i) 702-705
- Bavinck *et al* 1993 *Brit J Dermatol* **129** 242-249
- Wimmer *et al* 2007 *Kidney International* **71** 1271-1278
- Christenson *et al* 2004 *Dermatol Surg* **30** 598-603
- Casabonne *et al* 2009 *Int J Cancer* **125(8)** 1935-1945
- Campistol *et al* 2006 *J Am Soc Nephrol* **17** 581-589
- Harwood *et al* 2005 *Arch Dermatol* **141** 456-464
- Brown *et al* 2005 *Arch Dermatol* **141** 985-993
- Dragieva *et al* 2004 *Brit J Dermatol* **151** 196-200
- Perrett *et al* 2007 *Brit J Dermatol* **156** 320-328
- Wulf *et al* 2006 *Acta Derm Venereol* **86** 25-28
- Wennberg *et al* 2008 *Transplantation* **86** 423-429
- Ulrich *et al* 2008 *Am J Transplant* **8** 2192-2198

# Dermatology Meets Nephrology: Skin Care in Renal Transplant Recipients

## Interviewees

**GH:** Günther Hofbauer, MD



Department of Dermatology  
University Hospital Zürich  
Gloriastrasse 31  
8091 Zürich  
Switzerland

Tel: + 41-44-255-1111  
Email: hofbauer@usz.ch

**AS:** Andreas Serra, MD



Department of Internal Medicine  
Division of Nephrology  
University Hospital Zürich  
Rämistrasse 100  
8091 Zürich  
Switzerland

Tel: + 41-44-255-1111  
Email: andreas.serra@usz.ch

**Q:** Thank you both for being with us today. You wanted to label this interview 'Dermatology Meets Nephrology'. How did the two of you meet then?

**AS:** Ever since I started training in nephrology, I found transplantation a fascinating topic. I was impressed by the long survival times that our renal transplant recipients (RTRs) had achieved by improved organ procurement and immunosuppressive regimens over time. Some of them managed to have a donor kidney work for more than two decades. The price that some of our RTRs had to pay for such success was literally obvious, however: many of them developed skin changes such as early wrinkling, pigmentation changes, atrophy and eventually skin cancer...

**GH:** ...and that was when we met. Not much before this, I had set up an organ-transplant recipient specialty clinic, because our Dermatology Department had noticed the increasing numbers of transplant recipients seeking dermatological attention for mainly squamous cell carcinoma of the skin (SCC). Most of them were RTRs. Soon, we realised that dermatological care in RTRs should not just be about running behind the exploding numbers of SCC, cutting them out as they appeared, but rather it should start before transplantation, with a whole-body skin examination and education of the future transplant recipient about the importance of UV light as a carcinogen.

**AS:** As a consequence, our procedures for potential transplant recipients were modified to include a pre-transplantation dermatological consultation for potential recipients and even living donors. We think that this was a good choice, as photoprotection by behaviour, clothing and sunscreens could be best explained early in the transplant process. We did filter out the odd patient with SCC, basal cell carcinoma (BCC), melanoma or other skin cancers in need of treatment before transplantation. This is the best time for surgery, which is not complicated by immunosuppression and other concurrent problems.

**Q:** This sounds like two lonely physicians meeting in a small niche? How did you learn more about RTRs and their skin problems?

**AS:** Some of it was learning by doing. My summary after these years would be that common diseases seem to occur in uncommon presentations and that the exceptional course becomes the rule. With regard to the skin, we mainly worry about SCC and other skin

cancers in our RTRs, but are also confronted with viral and fungal infections, and less so with infections of bacterial origin.

**GH:** I was a resident when I started our dedicated out-patient clinic a decade ago. Still, after a short time, I had trouble finding help within my department for the special problems that RTRs brought with them. That's when I discovered the power of networking. As early as 2000, dermatologists from France, Italy and Germany came together with the common goal of skin care in organ transplant recipients, and formed **SCOPE** (Skin Care in Organ transPlant recipients Europe; [www.scopenetwork.org](http://www.scopenetwork.org)) in 2002. SCOPE holds yearly meetings, addressing clinical and basic research questions. I started to attend SCOPE meetings and found answers to questions from other specialists in this small corner of dermatology.

**Q:** What were the key messages that came back to your local hospital from this exchange with European dermatologists?

**AS:** I well remember Günther starting to suggest changes to the immunosuppressive regimens. Calcineurin inhibitors such as ciclosporin and tacrolimus have been the cornerstone to prevent rejection in RTRs. Suddenly, our dermatologist kept suggesting switching established drug regimens to mTOR inhibitors such as sirolimus.

**GH:** Rudolf Wüthrich, the head of the nephrology division, suggested that we should participate in an international multi-centre trial initiated by the French SCOPE member, Sylvie Euvrard, to study the dermatological benefit of switching from calcineurin inhibitors to mTOR inhibitors to slow down SCC formation in RTRs...

**AS:** ...and so we did! While the studies for mTOR inhibitors against SCC are still running, we have come to consider a switch to mTOR inhibitors for RTRs with a history of more than 10 SCCs, or more than 3 new SCCs occurring annually. For Kaposi's sarcoma, the switch to mTOR inhibitors is our first-line treatment, which is able to cure or halt the disease in most patients.

**Q:** You mentioned basic research being a topic in SCOPE meetings. How did this influence your practice?

**GH:** I remember a seminal **Science** publication by Peter Karran's group in 2005, which showed

for the first time that azathioprine, a traditional antimetabolite, increases photosensitivity of the skin to UVA and enables direct DNA damage by UVA, casting a new light on azathioprine as a contributor to SCC formation in RTRs. SCOPE gave me the contacts to get in touch with this basic research group...

**AS:** ...and we subsequently took these findings from bench to bedside. We discovered that UVA photosensitivity was indeed about doubled in our RTRs on azathioprine. In an interventional trial, we switched these patients away from azathioprine and found that their photosensitivity returned to normal levels within three months. In particular in RTRs with a high degree of SCC formation, substituting azathioprine may help to cut down on the number of SCCs occurring in the future. SCOPE was essential in linking us with basic scientists for this work.

#### **Q: Did SCOPE also inspire clinical observations to be turned into research?**

**GH:** One SCOPE meeting took place in the lovely venue of Venice. One night, I found myself by the fireplace of an elegant Venetian palace and our conversations turned to the impression that tenderness of skin lesions seemed a good indicator for SCC in transplant recipients...

**AS:** In Zürich and Leiden, we have now analysed several hundred lesions in transplant recipients for tenderness and verified their diagnosis by histology. It turns out that pain may be nearly as good an indicator for an SCC as the experienced dermatologist's clinical judgment. This may seem tough on the dermatologist, but is a clinical pearl that helps us nephrologists to better assess our RTRs' skin lesions.

#### **Q: You mentioned networking as an important part of the care for RTRs. What other resources can you tap into?**

**GH:** SCOPE is not the only interest group for skin and transplant recipients. **ITSCC**, the International Transplant Skin Cancer Collaborative, is a US-based group that holds yearly meetings and biannual retreats which are great platforms to learn and exchange. They also run a listserv, where all members can post questions to the community ([www.itssc.org](http://www.itssc.org)). Other ITSCC members share their opinions, experiences and suggestions in a matter of hours or days...

**AS:** ...which is of great help when we have to make tough calls on switching or even stopping immunosuppression in difficult cases with advanced skin cancer. Data from our patients was also incorporated into a recent SCOPE publication on the course of melanoma in organ transplant recipients: It seems that melanoma up to 2mm Breslow fares no worse than in the general population.

#### **Q: You mentioned immunosuppression as an important point to modulate in skin**

#### **cancer in RTRs. What can you offer your patients before they get to this point?**

**AS:** Well, we first of all make sure that all RTRs are offered skin examination and education about photoprotection. An impressive tool for educational purposes has been made available by the ITSCC group and is called the at-risk alliance ([www.at-risk.org](http://www.at-risk.org)). We are striving to have a similar tool adjusted for use in Switzerland: no easy feat, considering we have four national languages...

**GH:** Beyond primary prevention by education, we focus on secondary prevention. We try to pick up in-situ lesions such as actinic keratosis, Bowen's disease or porokeratosis as early as possible. Typically, we see multiple lesions because chronic UV damage leads to field cancerisation of the skin. When treating these early lesions, we aim beyond the individual lesion and try to address the whole field. Some patients do well with self-administered 5-fluorouracil or imiquimod, while others benefit from cryotherapy which is quick and easy to apply by the physician, but hard to distribute evenly over a larger area. Photodynamic therapy (PDT) is a good option in extensive disease and works particularly well on the head where many of our patients are affected by large numbers of in-situ lesions. Here, PDT helps to turn back the clock. The effect lasts for six months or longer, and then lesions start to reappear. Unlike other treatments, however, PDT is not limited in the number of applications that can be given and can thus provide repeat benefit for RTRs.

#### **Q: We have now come a long way from where you first met to where you stand today. Where will you go in the future?**

**AS:** We realise how tedious photoprotection is for our RTRs. Protection around the clock and from the inside would be desirable. More than a dozen of our RTRs have now been enrolled in a multinational trial which aims to provide internal photoprotection by the alpha MSH analogon afamelanotide.

**GH:** Time will tell whether this probably well tolerated compound may provide added benefit against SCC and its precursors in RTRs. With regard to the outside of the body, we are continuously working with pharmaceutical companies to improve sunscreens and to study their benefit in SCC prevention. Both studies, again, were in large parts facilitated by the SCOPE network mentioned above.

**AS:** In summary, we try to shift our efforts in RTRs and skin cancer to an earlier point on the time axis, away from catastrophic cutaneous carcinogenesis towards improved primary and secondary prevention. To further this goal, we assembled the Swiss societies of Dermatology, Nephrology and Transplantation and recently published 'Swiss clinical practice guidelines for skin cancer in organ transplant recipients', aiming to improve knowledge in this fascinating niche where dermatology meets nephrology. ■

## Showcase SCOPE

### About SCOPE

#### *The SCOPE Network*

Aftercare in organ-grafted patients still focuses on prevention and therapy of organ rejection.

Nowadays, with increasing survival times of allografted patients, regular dermatological checkups become more and more important.

While in the first year following transplantation special emphasis is given to the prevention of viral, bacterial and fungal infections, a significantly increased incidence of non-melanoma skin cancer is paralleling the extended survival rates of allografted patients. Cancer is now responsible for a mortality rate of 5-8% in these patients.

Accounting for almost 50% of all malignancies in transplant recipients, non-melanoma skin cancers, especially squamous cell carcinomas (SCC) and its precursor lesions, actinic keratoses (AK), represent the great majority of OTR cancers.

The SCOPE Network is designed as an interdisciplinary Network of dermatologists, transplant physicians, patient support groups and basic researchers brought together to meet the increasing need for qualified dermatological aftercare in this specialist group of patients. The SCOPE Network evolved in 2000 on a national level (France, Italy, Germany) and subsequently expanded on a European level in 2002.

Close cooperation at an international level with our sister organisation, the North American and Australian ITSCC (International Skin Cancer in Organ Transplant Patients Collaborative Group), represents an integral part of our network and emphasises the need for global collaboration in the field of transplant dermatology.

**Günther Hofbauer  
and Catherine Harwood**  
*Secretaries  
European SCOPE Network*

# 12th World Congress of the International Photodynamic Association (IPA)

11-15 June, 2009, Seattle, USA

by:

**Dr Alison Curnow**  
(Peninsula Medical School  
University of Exeter, Truro, UK)

**Dr Dominic Robinson**  
(Erasmus MC, Rotterdam  
The Netherlands)

and

**Dr Zheng Huang**  
(University of Colorado  
Denver, USA)

Around 300 participants from more than 20 different countries and regions travelled to Seattle in June to attend the 12th IPA World Congress. This was co-organised locally by SPIE on behalf of the Congress President, **Professor David Kessel** (Detroit, USA), and his Organising Committee, which consisted of **Professors Tayyaba Hasan** (Boston, USA), **Chuck Gomer** (Los Angeles, USA) and **Kenneth Wang** (Rochester, USA). This Congress followed in the great tradition of these biennial conferences, which routinely attract leading clinical and scientific researchers in the fields of PDT and fluorescence diagnosis (FD) alike.

The IPA is an academic society whose membership consists of the most prominent international clinicians and scientists involved in performing and researching PDT and FD. It aims to promote the study of diagnosis and treatment using light and photosensitisers and to disseminate such information to the members of the IPA, the medical community and to the general public. The biennial World Congress therefore plays an important role in the activity of the Society and attendance is an excellent way to keep abreast of new developments in this rapidly evolving field.

## THURSDAY 11th JUNE

The meeting was officially opened by **Professor David Kessel** (Detroit, USA). Two plenary lectures then commenced the scientific portion of the day. The first was delivered by **Professor Ravi Pandey** (Buffalo, USA) on behalf of **Professor Tom Dougherty** (Buffalo, USA) and considered the role of the academic in the development

of new photosensitising drug formulations. This was followed by **Professor Julia Levy** (Vancouver, Canada) who drew on her own career to consider how PDT could be commercialised and thus brought to market as an effective therapy.

Concurrent, parallel sessions then commenced, with individual sessions bringing together work on the subjects of mechanisms of PDT toxicity, the 'variables' associated with PDT and the first of a series of 4 workshops, sponsored by Photocure ASA, on PDT and FD with porphyrin precursors. Highlights included presentations on the recent progress in photochemical internalisation from the Norwegian Radium Hospital, the development of dendrimer and peptide conjugates for aminolaevulinic acid (ALA)-PDT from University College London and the role of cancer stem cells in tumour side populations from the Roswell Park Cancer Institute.

**Dr Christian Betz** (Münich, Germany) and colleagues considered low dose mTHPC-PDT as a treatment option for basal cell carcinoma (BCC) and found that the largest sub-group they investigated ( $n = 80$ ) had a complete response rate of 100% at 8 weeks (following PDT treatment with 0.05mg/kg mTHPC, a drug-light interval of 48 hours and a light dose of 50J/cm<sup>2</sup>). Longer term results are still required however. **Professor Ann-Marie Wennberg** (Göteborg, Sweden) discussed the use of PDT as an early treatment for the multiple non-melanoma skin cancers (NMSC) and precancers frequently observed in immunosuppressed patients and **Professor Dr Rolf-Markus Szeimies** (Regensburg, Germany) considered PDT as a treatment for non-oncological dermatological conditions. He concluded that repeated topical ALA- or methyl aminolevulinic acid (MAL; Metvix®)-PDT is an effective treatment option for diseases of the pilosebaceous unit and other inflammatory skin diseases, but randomised controlled trials are required to demonstrate this efficacy more robustly.

## FRIDAY 12th JUNE

The second day started with another two very informative plenary sessions. **Professor**



Seattle skyline at night, showing the Space Needle Tower.

**Tayyaba Hasan** (Boston, USA) spoke about how molecular targeting could be used to enhance PDT treatment outcomes and then **Professor Steve Bown** (London, UK) talked about how PDT could be taken into mainstream clinical practice and the barriers that are currently inhibiting this translation from occurring on a larger scale.

The parallel sessions comprised of another three sessions on 'Clinical PDT', the final part of the Photocure-sponsored 'PDT and PD with Porphyrin Precursors' workshops, two sessions on 'Preclinical PDT', as well as single sessions on 'PDT Photo-physics', 'PDT Mechanisms' and 'PDT Techniques'. Highlights included a range of presentations on the role of ALA-PDT and fluorescence-guided resection in neuro-surgical applications, the role of PDT for the treatment of head and neck cancer, for pre-malignancies in the gastrointestinal tract and in dermatology.

Among the mechanistic and pre-clinical presentations, exciting data were presented on the use of MicroCT-guided protoporphyrin IX (PpIX) quantification in mouse tumours from Dartmouth College, USA, the use of photochemical internalisation combined with PDT from University College London and the complex area of singlet oxygen-based dosimetry in PDT from the University of Toronto.

**Dr Edward Maytin et al** (Cleveland, USA) have conducted a clinical pilot study to measure PpIX levels in skin cancer and pre-

cancer via *in vivo* fluorescence dosimetry. PpIX accumulation exhibited linear kinetics in actinic keratosis (AK) and progressive increases in PpIX levels were observed in normal skin, AK and squamous/basal cell carcinoma (SCC/BCC), respectively (measured *in vivo* and in biopsy specimens). In the same session, **Ms Jessica Tyrrell** (Truro, UK) presented the validation and utilisation of a non-invasive fluorescence imaging system to monitor clinical MAL-PDT of licensed dermatological lesions. Initial studies indicated that PpIX photobleaching during light irradiation corresponded to clinical outcome at follow-up.

**Professor Xiuli Wang** (Shanghai, China) presented a collaborative study (n = 30) where 73% clearance of moderate to severe acne vulgaris lesions was achieved with two cycles of 10% ALA-PDT and a drug light interval of 3 hours. **Dr Alison Curnow** (Truro, UK) presented a small clinical dose-escalation pilot study of iron chelation enhancement of nBCC MAL-PDT with the hydroxypyridinone iron-chelating agent, CP94, following extensive *in vitro* experimentation and concluded that this was a simple and safe modification which required further study to fully establish efficacy in these thicker lesions, which are more difficult to treat with the PDT treatment protocols that are currently being employed. **Dr Christina Halldin** (Göteborg, Sweden) showed a video of using nerve blocks as pain relief during topical PDT.



**Professor Tayyaba Hasan** (IPA Treasurer), **Dr Alison Curnow** (IPA Secretary-General) and **Professor Herwig Kostron** (13th IPA World Congress President) at the IPA Gala Dinner, held at the Seattle Space Needle.

## SATURDAY 13th JUNE

The final two invited plenaries took place on Saturday morning. **Professor Stanley Brown** (Leeds, UK) talked about the rapid clinical developments taking place in antimicrobial PDT and **Professor Herwig Kostron** (Innsbruck, Austria) gave an excellent overview of the role of PDT and PD in neurosurgery.

The following parallel sessions consisted of the final three sessions in the 'Clinical PDT' series, two sessions on 'Sensitiser Synthesis' and a session on 'PDT Photo-

physics and Nanotechnology'. Highlights included presentations on the use of photosensitiser lifetime contrast imaging in mice from Roswell Park, novel boron-containing phthalocyanines from the Universities of Louisiana State and Padova, and the role of PDT using porphyrin precursors in CIN, from Hannover, Germany.

**Dr Kai-Hua Yuan et al** (Guangzhou, China) compared haematoporphyrin monomethyl ester PDT with pulsed dye laser (PDL) retrospectively as a treatment for port wine stain birthmarks and found that the two therapies were equivalent for treating pink flat lesions of children (PDL n = 112, PDT n = 98) and PDT was more effective when treating purple flat lesions of adults (PDL n = 163, PDT n = 208). **Dr Patrycja Mikolajewska et al** (Oslo, Norway) reported a pilot study on pain sensations during the build-up and clearance phase of PpIX. Preliminary results suggested that it was less painful in the clearance phase for topical ALA and hexaminolevulinic acid (HEX; Hexvix®), but not for MAL.

A scientific panel decided to award four prizes to the following poster presentations:

- Development of a wide field reflectance and fluorescence imaging device for the detection of skin and oral cavity cancer.

**S Pratavieira, VS Bagnato and C Kurachi.**

*University of San Paulo, Brazil.*

- Molecular mechanisms associated with metronomic ALA-PDT in the brain.

**G Singh.**

*Juravinski Cancer Centre, Canada.*

- Efficacy and safety of PDT with Photolon (Fotolon): a seven-year clinical experience.

**TV Trukhachova, SV Shliakhtsin, PT Petrov, YP Isotomin, VN Chalau, DA Cerkovsky, LN Marchanko, AS Fedulov and MA Kaplan.**

*RUE Belmedpreparaty, Belarus, Research Institute of Oncology and Medical Radiology, Belarus and Medical Radiology Research Centre, Russian Federation.*

- Exploiting bacterial drug resistance: a single construct for the diagnosis and treatment of drug-resistant infections.

**UW Sallum, X Zheng, S Verma and T Hasan.**

*Wellman Centre for Photomedicine, USA.*

These prizes were presented by **Professor Kristian Berg** (Oslo, Norway) at the IPA Gala Dinner, which was held in the evening at one of the elevated restaurants of the Seattle Space Needle. Thanks were also given to **Professor Patrick Barron** (Japan) at this event by **Professor Steve Bown**

(London, UK) and the new IPA Secretary-General, **Dr Alison Curnow** (Truro, UK), for his 23 years of committed service as IPA Secretary-General. We believe all attendees enjoyed this event and the 360° views of Seattle at sunset were spectacular.

## SUNDAY 14th JUNE

Concurrent sessions comprised of a series of four sessions on 'Antimicrobial PDT'. This exciting field of PDT research has been growing rapidly over recent years and excellent presentations were given by a number of investigators. During the day, sessions on 'PDT Dosimetry', 'PDT Evaluation Techniques', 'PDT: New Approaches' and 'PDT Targeting' were well attended. Highlight presentations described the use of MR-guided diffuse fluorescence tomography for monitoring verteporfin PDT in mice, from Dartmouth College, USA, peptide-conjugated multi-functional nano-photomedicines for targeted PDT, from Rotterdam, The Netherlands, and the role of the bystander effect in *in vitro* PDT from the University of Nantes, France.

**Professor Tayyaba Hasan** (Boston, USA) also discussed the potential of new phenothiazine photosensitisers as an effective treatment for cutaneous leishmaniasis without scar formation.

## MONDAY 15th JUNE

The final day of the Congress closed at lunchtime, following the final double parallel sessions on 'PDT Biophysics' and 'Preclinical PDT Methodology'. Highlight presentations included studies measuring singlet oxygen in *in vitro* and *in vivo* environments and the use of biodegradable nanoparticles as carriers for PDT agents, from Berlin and Frankfurt, Germany.

**Dr Sanjay Anand et al** (Cleveland, USA) described animal models where preconditioning with methotrexate or topical vitamin D application (both of which promote differentiation) improved the effectiveness of ALA-PDT. **Dr Brian Pogue et al** (Dartmouth College, USA) combined high-frequency ultrasound imaging with multifibre fluorescence tomography to quantify PpIX fluorescence in skin and skin tumour layers.

Conference abstracts are available online at the IPA and SPIE websites. There is a SPIE publication (*SPIE Proceedings*, Vol. 7380) of short manuscripts, provided by the participants of the Congress, available for purchase for anyone who would like to know more details of the content of this meeting.

We greatly look forward to the 13th IPA World Congress (Innsbruck, Austria, 10-14 May, 2011). Further details about this meeting, the IPA and how to become an IPA member can be found on the **IPA website:**

<http://www.pms.ac.uk/ipa>